A NOVEL MORPHOLOGIAL-BASED CAROTID ARTERY CONTOUR EXTRACTION

Amr R. Abdel-Dayem and Mahmoud R. El-Sakka
Computer Science Department
The University of Western Ontario
London, Ontario, Canada
{amr, elsakka}@csd.uwo.ca

Abstract

Ultrasound imaging provides an inexpensive tool for monitoring the blood flow within the carotid artery. The precipitation of plaque on the wall of the carotid artery has a great influence on the blood flow within the artery. Due to the poor quality and the presence of noise in ultrasound images, manual extraction of carotid artery walls is a tedious and time-consuming task.

In this paper, a novel carotid artery contour extraction is proposed. The proposed scheme consists of four major stages. These stages are: pre-processing stage, quantization stage, morphological contour detection stage, and finally a contour enhancement stage.

Experimental results over a set of sample images showed that the proposed scheme produces accurate contours. Thus the proposed scheme can be used as an effective tool in monitoring and detecting plaque precipitation on the walls of the carotid artery.

Keywords: *Morphology operations - Contour detection - Computer aided diagnostic - Plaque precipitation.*

1. INTRODUCTION

According to the heart and stroke foundation of Canada, there are over 70,000 heart attacks in Canada each year. Every year, about 19,000 Canadians die from heart attacks. The precipitation of plaque on the wall of the carotid artery is one of the major causes of heart attacks. Moreover, it may lead to stenosis of the artery. Early detection of precipitation of plaque plays an important role in preventing serious heart problems. It would be valuable to introduce a *computer aided diagnostic* technique (CAD) for better detection and diagnosis of carotid artery stenosis.

1.2 The Problem Statement

Currently, ultrasound imaging is used heavily to detect the existence of plaque on carotid artery walls. The main drawback of ultrasound imaging is its poor quality. It takes considerable effort from a radiologist to extract significant information about carotid artery walls and the possible existence of plaque layers that may exist. This task requires a highly skilled radiologist. Furthermore, manual extraction of carotid artery walls generates a result that is not reproducible. Thus, automatic detection of carotid artery wall is highly appreciated.

1.3 Background

Mao *et-al.*, in [1], proposed a deformable model-based method for extracting carotid artery lumens in two-dimensional ultrasound images. The proposed method generated the initial contour from the entropy map of the original image and a user specified seed point. The major drawback of the proposed method is that the time complexity of deformable models is relatively high.

Abolmaesumi *et-al.*, in [2], introduced an algorithm for extracting carotid artery boundaries in real-time. The proposed algorithm was based on the use of both temporal and spatial Kalman filters to track the center and the walls of the artery.

Da-chuan *et-al.*, in [3], proposed a method for automatic detection of *intimal* and the *adventitial* layers of the common carotid artery wall in ultrasound images using snake model. The proposed method modified the Cohen's snake by adding some special criteria to obtain the contour with the global maximum cost function. The proposed snake model was compared with a ziplock snake and was found to give superior performance. However, the computational time for the proposed model was significantly high. It took long time for the snake to reach the optimum shape.

CCECE 2004- CCGEI 2004, Niagara Falls, May/mai 2004
0-7803-8253-6/04/$17.00 ©2004 IEEE

Authorized licensed use limited to: ShanghaiTech University. Downloaded on September 20,2025 at 09:15:25 UTC from IEEE Xplore. Restrictions apply.

Hamou *et-al.*, in [4], proposed a new scheme for detecting the plaque regions in carotid artery ultrasound images. The proposed method is based on a canny edge detection scheme. However, in the proposed algorithm, the user has to specify three threshold parameters. Thus, the proposed algorithm is less user-friendly and the accuracy of the results depends, to a large extent, on the appropriate selection of these parameters.

In this paper, we propose a novel scheme for carotid artery contour extraction. The proposed scheme is fully automated with efficient execution time and powerful results.

1.4 Paper Layout

This paper is organized as follows. Section 2 describes the proposed scheme in detail. Section 3 introduces the results produced by the proposed scheme. Finally, Section 4 offers the paper conclusions.

2. THE PROPOSED SOLUTION

We propose a novel system for the extraction of the carotid artery wall. Figure 1 shows the block diagram for the proposed system. The method is fully automated. There is no input from the user. The idea is based on extensive use of morphological operations. In the following subsections, a brief description of each stage is introduced.

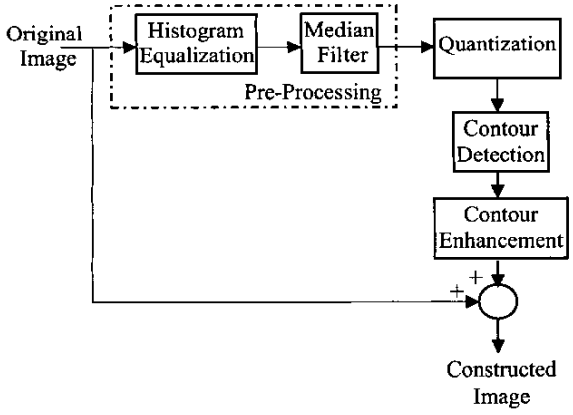

Figure 1: The block diagram of the proposed scheme

2.1 The Pre-Processing Stage

The objective of this stage is to improve the quality of the input image as much as we can. First, a histogram equalization step is performed [5]. The effect of this step is to increase the dynamic range of gray levels. Thus it results in an increase in the image contrast. Second, a median filter is used to reduce the speckle noise that usually exists in ultrasound images. It was found empirically that a 3×3 median filter is suitable for the removal of most of the speckle noise without severely affecting the quality of the edges in the image. During the design phase of our system, we established a clean separation between the pre-processing stage and the remaining stages of the system. This allows our system to be interfaced with any noise removal schemes [6]-[9] without disturbing the main operation of the system.

2.2 The Quantization Stage:

In this stage, the pre-processed image is uniformly quantized using three levels of quantization. The decision boundaries of the quantizer are equally spaced and the reconstruction level for each interval was selected to be the intensity value at the center of the interval. The effect of the quantization stage is to cluster the image pixels into three virtual objects. These three objects nearly approximate: 1) the area inside the artery, 2) the artery wall and 3) the plaque layers. Another important effect of this stage is the reduction of the noise that still exists following the pre-processing stage. During careful inspection of the noise within ultrasound images, we noticed that the value of a corrupted pixel usually belongs to the context of its surrounding pixels. Thus, the quantization step will assign this pixel a value that is similar to its surrounding pixels. This stage is the base step toward the success of the contour detection phase.

2.3 Contour Detection Stage

The objective of this stage is to estimate the carotid artery contour. In the proposed scheme, a morphology contour detector is used [5], [10]. First, the quantized image is morphologically eroded. Then, the eroded image is subtracted from the quantized one to obtain a set of contours representing the boundaries between the different tissues of the artery. This stage can be described by the following equation:

$$\text{Boundary}(A) = A - (A \,\theta\, B), \qquad (1)$$

where, A is the quantized image, B is the structuring element and θ is the erosion operator.

During this study, structuring elements with different shapes and sizes were tried. It was found that the shape of the structuring element has little or no effect on the resulting contours. However, the size of the structuring element is an important factor. Smaller element sizes resulted in thinner contour with greater detail. It was found that a 3×3 square structuring element gave the best results (more detail) in most of the cases.

Authorized licensed use limited to: ShanghaiTech University. Downloaded on September 20,2025 at 09:15:25 UTC from IEEE Xplore. Restrictions apply.

2.4 Contour Enhancement Stage

The objective of this stage is to smooth the contours obtained from the previous stage and to fill any gaps that may exist in the artery contour. These gaps are mainly due to the shadow effect that is usually present in ultrasound images. Thus, a morphological opening operation is used to fill in such gaps. Usually, the size of these gaps is relatively small. The size of the structuring element is a matter of contour distortion and gap filling trade-offs. It was found empirically that a 5×5 structuring element is sufficient enough to fill up most of these gaps without severely degrading the resulting contour.

3. RESULTS

The proposed system was tested using a set of B-mode ultrasound images of various carotid arteries. These images were obtained using ultrasound acquisition system (Ultramark 9 HDI US machine and L10-5 linear array transducer) and digitized with a video frame grabber before saved to disk. These images include patients with different ages and different degrees of plaque precipitations. Figure 2 shows a sample of these images.



Figure 2: Original carotid artery ultrasound image

Figure 3 shows the image in Figure 2 after the histogram equalization step. The image contrast is increased and the improvement over the original image is quite evident. Figure 4 shows the histogram-equalized image after applying the median filter. The median filter reduced the amount of the speckle noise and produced a relatively clear image for further processing. Figure 5 shows the image after the quantization phase. The image contains three levels of intensities representing rough estimates of the major three layers that exist in the ultrasound image. Figure 6 shows the output from the contour detection phase.

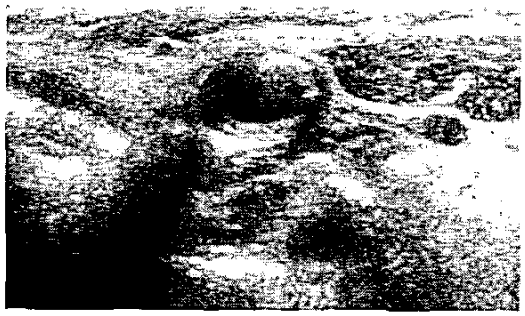

Figure 3: The image in Figure 2 after the histogram equalization phase.

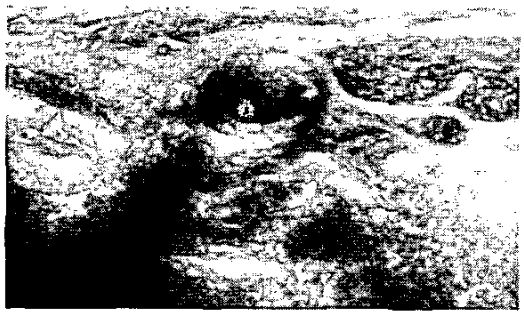

Figure 4: The US image after the pre-processing stage



Figure 5: The US image after the quantization stage

Figure 6: The US image after the contour detection stage

Authorized licensed use limited to: ShanghaiTech University. Downloaded on September 20,2025 at 09:15:25 UTC from IEEE Xplore. Restrictions apply.

The resulting contour is not smooth and some noise exists within the region of interest (ROI). This is the role of the contour enhancement phase, which fills in the gaps in the resulting contour and removes any remaining noise in the ROI. Figure 7 shows the output from the contour enhancement stage. Finally, Figure 8 shows the histogram-equalized image with the resultant contour imposed on it.

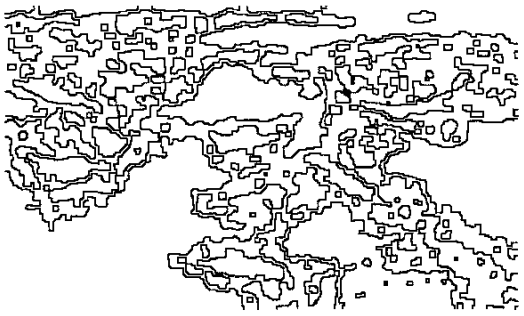

Figure 7: The output from the contour enhancement stage

Figure 8: The histogram equalized image with the resulting contour

4. CONCLUSIONS

In this paper, a novel carotid artery contour extraction from ultrasound images was introduced. The results generated by the proposed schemes are considered an excellent contour estimator. The novelty of this scheme stems from the fact that it depends only on a set of primitive morphological operations. Thus, the implementation of our scheme is relatively simple and the time complexity for running the algorithm is much simpler than deformable model-based schemes. Furthermore, the hierarchical structure of our scheme allows it to be interfaced with any pre- or post-processing stages for further improvements.

Acknowledgements

The authors would like to thank *The Robarts Research Institute* at the University of Western Ontario for providing us with the ultrasound images used to test the proposed scheme.

References

[1] F. Mao, J. Gill, D. Downey, A. Fenster, "Segmentation of carotid artery in ultrasound images", Proceedings of the 22nd IEEE Annual International Conference on Engineering in Medicine and Biology Society, vol. 3, pp.1734 – 1737, July 2000.

[2] P. Abolmaesumi, M. Sirouspour, S. Salcudean, "Real-time extraction of carotid artery contours from ultrasound images", Proceedings of the 13th IEEE Symposium on Computer-Based Medical Systems, pp.181– 186, June 2000.

[3] C. Da-chuan, A. Schmidt-Trucksass, C. Kuo-Sheng, M. Sandrock, P. Qin, H. Burkhardt, "Automatic detection of the intimal and the adventitial layers of the common carotid artery wall in ultrasound B-mode images using snakes", Proceedings of the International Conference on Image Analysis and Processing, pp. 452 – 457, September 1999.

[4] A. Hamou and M. El-Sakka, "A Novel Segmentation Technique For Carotid Ultrasound Images", International Conference on Acoustics, Speech and Signal Processing, ICASSP 2004, May 2004.

[5] G. Gonzalez, E. Woods, "Digital Image Processing", Addison-Wesley, 1992.

[6] C. Chinrungrueng, A. Suvichakorn, "Fast edge-preserving noise reduction for ultrasound images", IEEE Transactions on Nuclear Science, vol. 48, no. 3, pp. 849-854, June 2001.

[7] D. Vitale, G. Lauria, N. Pelaggi, G. Gerundo, C. Bordini, D. Leosco, C. Rengo, F. Rengo, "Optimal number of averaged frames for noise reduction of ultrasound images", Proceedings of the Computers in Cardiology, pp. 639 –641, September 1993.

[8] A. Suvichakorn, C. Chinrungrueng, "Speckle noise reduction based on least squares approximation", The IEEE Asia-Pacific Conference on Circuits and Systems, pp. 430 –433, December 2000.

[9] O. Michailovich, D. Adam, "Robust estimation of ultrasound pulses using outlier-resistant de-noising", IEEE Transactions on Medical Imaging, vol. 22, no. 3, pp. 368-381, March 2003.

[10] E. Dargherty, R. Lotufo, "Hands–on Morphological Image Processing", The society of Photo-Optical Instrumentation Engineers, 2003.

Authorized licensed use limited to: ShanghaiTech University. Downloaded on September 20,2025 at 09:15:25 UTC from IEEE Xplore. Restrictions apply.